Rheumatic heart disease from classroom to bedside

5th year lecture series

Activate Windows
Go to PC settings to activate Windows.

A
You

9:31

REC

DEFINITIONS

- Delayed nonsuppurative sequelae of upper respiratory tract infection with group A beta hemolytic streptococcus.
- Post infectious or connective tissue disease.
- A diffuse inflammatory disease of the connective tissue involving chiefly the heart, joints, blood vessels, and subcutaneous tissues.

Activate Windows
Go to PC settings to activate Windows.

A

You

9:32

REC

Background information

- Rheumatic heart disease , a sequel of rheumatic fever that follows untreated group A streptococcal pharyngitis in young susceptible individuals
- Rheumatic heart disease remains a global health problem in low- and middle-income countries.
- Recent studies in school children have reported the prevalence as high as 21.5–30.4 cases per 1000.
- 5th leading cause of cardiovascular mortality in adults
- 6th leading cause of cardiovascular morbidity in Africa

Activate Windows
Go to PC settings to activate Windows.

A

You

REC

AETIOLOGY & EPIDEMIOLOGY

- Group A streptococcus the aetiologic precursor
- Role of constitutional and environmental factors unknown
- Familial susceptibility is significant
- Malnutrition, overcrowding and lower socioeconomic status seem to predispose to streptococcal infections and subsequent rheumatic attacks

Activate Windows
Go to PC settings to activate Windows.

A

You

REC

THE STREPTOCOCCUS AND CONCEPT OF ANTIGENIC MIMICKRY

- Tissue injury mediated by immune reaction
- streptococcal capsule - human joint
- cell wall(M-proteins) – Myocardium
- Cell wall carbohydrate- valvular tissue
- Cytoplasm- myocardium sarcolemma , subthalamic body & caudate nuclei

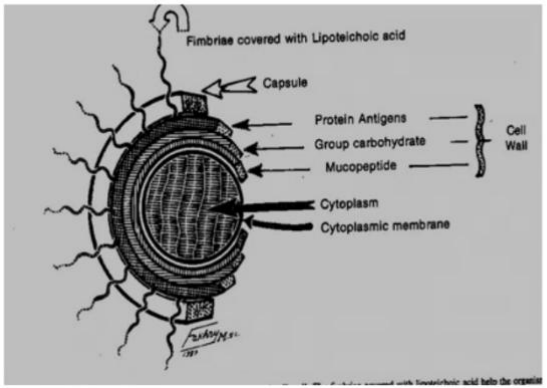

Activate Windows
Go to PC settings to activate Windows.

You

Mechanism of tissue injury and pathogenesis of rheumatic fever

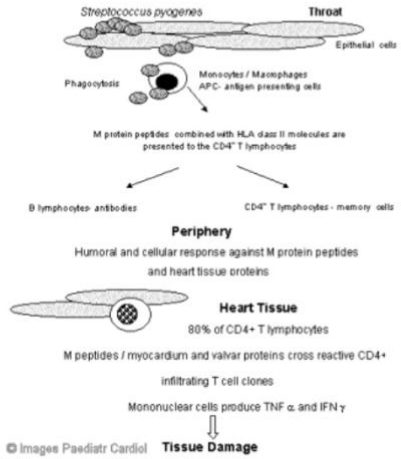

© Images Paediatr Cardiol

GROUP A STREPTOCOCUS(rheumatogenic strains M1,3,5,6,18 mucoid)

SUSCEPTIBLE HOST (positive for HLADR4,2,1,3,7, Dw10)

TISSUE/ORGAN (inflammation of Heart, Joints, Brain, Vascular and connective tissue)

IMMUNE REACTION (Cross-reactive antibody and/or cell mediated immunity)

RHEUMATIC FEVER

Activate Windows
Go to PC settings to activate Windows.

9:38
REC
A
You

9:40

REC

Clinical profile in Paediatrics

- Regurgitant lesion- Mitral & Aortic **(5- 10yrs)**
- Mixed lesions Mitral regurgitation & MS, aortic regurgitation

(10- 15)

Stenotic lesions - Mitral stenosis/ aortic regurgitation, Aortic stenosis

>15yrs

Activate Windows
Go to PC settings to activate Windows.

A

You

9:44

REC

The mitral valve anatomy and physiology

- Leaflets, chordae and papillary muscles

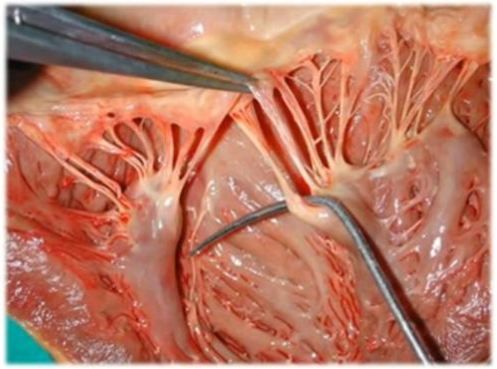

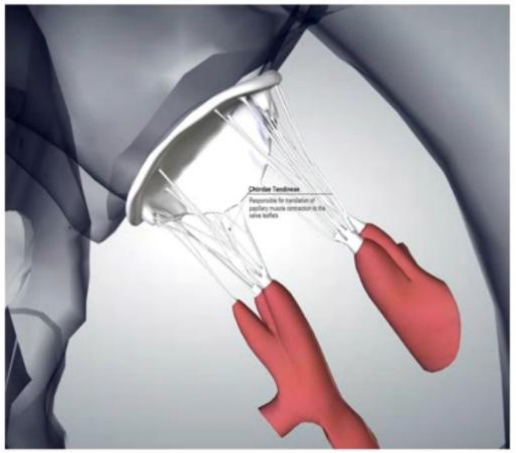

Activate Windows
Go to PC settings to activate Windows.

You

9:46

REC

Physiology of mitral regurgitation

- The mitral valve opens in diastole to allow blood to enter from the the left atrium to left ventricle
- During ventricular systole the mitral valve closes to prevent blood going back to left atrium
- Mitral regurgitation is a systolic leak back to the left atrium and pulmonary circulation
- Volume overload of both LV &LA
- The leak starts at the onset of ventricular contraction till the end --- PANSYSTOLIC
- Best heard at the apex
- The leak is to LA—RADIATION TO AXILLA
- during diastole the distended left atrium empties into LV

Activate Windows
Go to PC settings to activate Windows.

A

You

9:50

REC

Clinical presentation of Rheumatic Mitral regurgitation

Symptoms

- Fatigue, and poor exercise tolerance, weakness, weight loss
- Palpitations and chest pains
- Cough and difficulty in breathing
- Asymptomatic in mild MR
- Most common valvular involement in the younger age group

signs

Normal to low volume pulses

JVP not elevated

Heaving hyperactive apical apex

First heart sound normal , 2nd HS accentuated with increasing pulmonary hypertension

Apical pansystolic murmur grade 2-6 radiating to axilla

Activate Windows
Go to PC settings to activate Windows.

A

You

9:52

REC

Investigations and management

- CXR cardiomegaly with increased pulmonary vascular markings
- ECG- Left ventricular hypertrophy, LAE
- Echo- Defines the pathology and severity of the regurgitation
- Medical management of heart failure
- Prevention of recurrences of RF
- Surgical treatment- Repair or replacement of the mitral valve

Activate Windows
Go to PC settings to activate Windows.

A

You

Pathology of mitral stenosis

MITRAL VALVE APPARATUS

- Thickening of the leaflets
- Fibrosis
- Fusion of the commissures with associated immobility
- Calcification

ADDITIONAL FINDINGS

- Dilated left atrial chambers
- Hypertrophied and dilated right ventricle
- Severe pulmonary congestion and edema
- Pulmonary venous hypertension, pulmonary arterial hypertension
- Lung fibrosis and lackof compliance

Activate Windows
Go to PC settings to activate Windows.

9:53
REC
A
You

Pathophysiology

- Restricted ventricular filling, producing a pressure gradient between LA and LV
- Diastolic murmur
- Mid diastolic murmur at apex
- No radiation
- LA enlargement

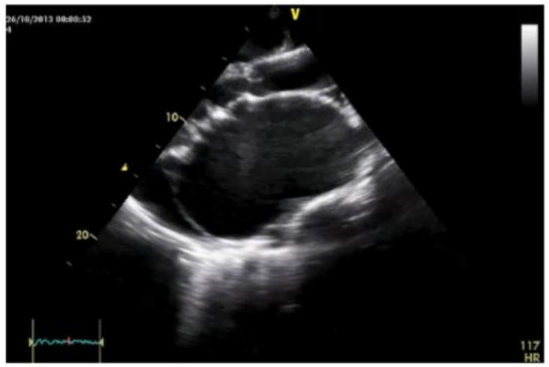

Activate Windows
Go to PC settings to activate Windows.

9:54
REC
A
You

9:56

REC

Clinical presentations

- Asymptomatic if mild
- Dyspnoea, orthopnoea, and palpitations
- Symptom mimickry- stroke in the young
- Irregular and low volume pulses
- Palpable P2, tapping apex, right parasternal heave
- Loud P2, opening snap, apical mid diastolic murmur
- Chest crepitations and hepatomegaly

- Chest X ray – pulmonary venous congestion
- Interstitial edema- Kerleys B line
- Increased pulmonary vascularity in the upper lobes

- Left atrium and right ventricular enlargement
- Prominent pulmonary artery

Activate Windows
Go to PC settings to activate Windows.

A

You

Complications of mitral stenosis

- Atrial fibrillation
- Stroke
- Intractable CCF

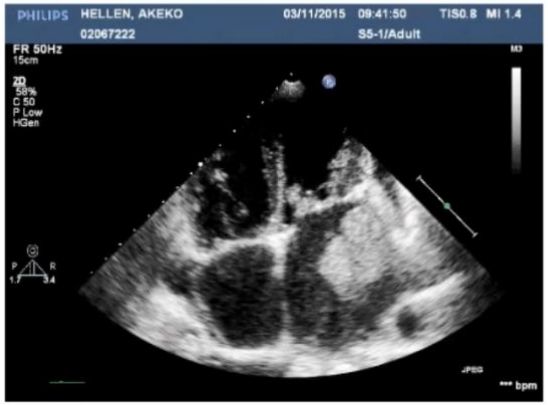

Activate Windows
Go to PC settings to activate Windows.

9:59
REC
A
You

10:00

REC

Mixed mitral valve disease

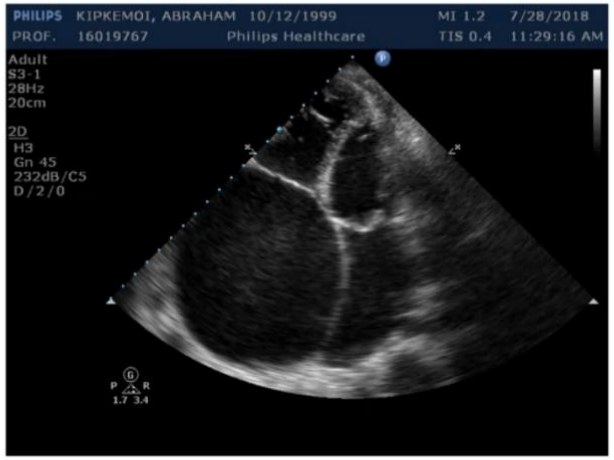

Activate Windows
Go to PC settings to activate Windows.

You

10:01

REC

Management of mitral stenosis

- Medical
- Restrict physical activity
- Manage atrial fibrillation with anticoagulation- warfarin
- Slow the heart rate –digoxin
- Recognise and Manage pulmonary edema

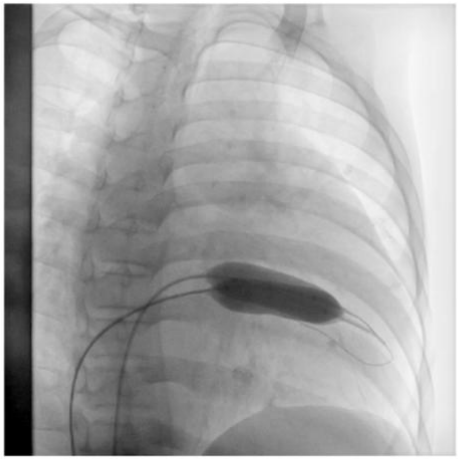

Activate Windows
Go to PC settings to activate Windows.

A

You

10:02

REC

Surgical Management of mitral stenosis

- Surgical- Closed valvotomy
- - Open valvotomy
- - Mitral valve repair
- - Mitral valve replacement

Activate Windows
Go to PC settings to activate Windows.

A

You

10:03

REC

Aortic valve disease

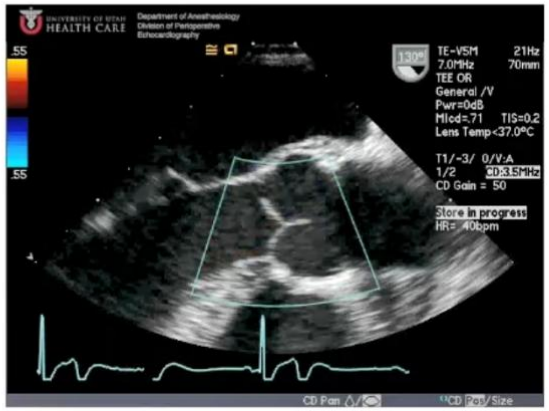

- Aortic valve opens in systole and closes in diastole
- Has three leaflets which are equal
- Pathology involves deformation, fibrosis, thickening and retraction
- Lesions mainly regurgitation
- Isolated AS -Congenital

Activate Windows
Go to PC settings to activate Windows.

A

You

10:05

REC

Clinical manifestations of Aortic regurgitation

Symptoms

- Mild regurgitation asymptomatic
- Moderate to severe- poor exercise tolerance with dyspnoe
- Angina
- Features of chronic heart failure

- **Examination**
- Bounding, collapsing pulses- wide pulse
- The Corrigan's pulse of femoral artery
- Capillary pulsations- Quinkes pulse
- Piston shots
- Duroziezs sign
- The Corrigan's sign
- Wide pulse pressure

Activate Windows
Go to PC settings to activate Windows.

A

You

10:08

REC

Aortic regurgitation

- Apex beat – displaced downwards and laterally
- Diastolic thrill along the left sternal border
- High pitched & blowing early diastolic murmur along left upper sternal border and radiates widely to the lower sternal border
- The longer the murmur the more severe the regurgitation

- CXR – cardiomegaly, LV prominence, Dilated ascending aorta, Prominent aortic Knob
- ECG- LVH
- Echo- Dilated LV, Normal LA
- Abnormal aortic leaflet pathology

Activate Windows
Go to PC settings to activate Windows.

A

You

10:10

REC

Management

- Medical
- Restrict physical activities
- Afterload reduction with ACE inhibitors in absence of HF
- If in heartvfailure add diuretics, digoxin

Surgical

- Aortic valve replacement using
  - Mechanical Prosthesis
  - Tissue valves- bovine and porcine
  - Pulmonary root autograft
  - Homograft

Activate Windows
Go to PC settings to activate Windows.

A

You

10:14

REC

Truths about RHD

- A bad disease
- Onset in childhood terrible and debilitating
- No Cure
- Current therapies only shortlive
- The best treatment is aggressively managing the streptococcal pharyngitis

Activate Windows
Go to PC settings to activate Windows.

A

You

10:15

REC

- Thank you.

Activate Windows
Go to PC settings to activate Windows.

A

You